

Clinical and microbiological efficacy of micafungin on *Geosmithia argillacea* infection in a cystic fibrosis patient

Christophe Marguet, Loïc Favennec, Olivier Matray, Sébastien Bertout, Sandrine Giraud, Laure Couderc, Rachid Zouhair, Christine Leguillon, Gilles Gargala, Jean-Jacques Ballet, et al.

► To cite this version:

Christophe Marguet, Loïc Favennec, Olivier Matray, Sébastien Bertout, Sandrine Giraud, et al.. Clinical and microbiological efficacy of micafungin on *Geosmithia argillacea* infection in a cystic fibrosis patient. *Medical Mycology Case Reports*, [Amsterdam]: Elsevier, 2012, 1 (1), pp.79 - 81. 10.1016/j.mmcr.2012.08.004 . hal-03134624

HAL Id: hal-03134624

<https://hal.univ-angers.fr/hal-03134624>

Submitted on 8 Jun 2021

HAL is a multi-disciplinary open access archive for the deposit and dissemination of scientific research documents, whether they are published or not. The documents may come from teaching and research institutions in France or abroad, or from public or private research centers.

L'archive ouverte pluridisciplinaire **HAL**, est destinée au dépôt et à la diffusion de documents scientifiques de niveau recherche, publiés ou non, émanant des établissements d'enseignement et de recherche français ou étrangers, des laboratoires publics ou privés.





Clinical and microbiological efficacy of micafungin on *Geosmithia argillacea* infection in a cystic fibrosis patient

Christophe Marguet^a, Loïc Favennec^{b,*}, Olivier Matray^b, Sébastien Bertout^c,
Sandrine Giraud^d, Laure Couderc^a, Rachid Zouhair^d, Christine Leguillon^a, Gilles Gargala^b,
Jean-Jacques Ballet^b, Jean-Philippe Bouchara^{d,e}

^a Unité de pneumologie et d'allergologie pédiatrique, Département de pédiatrie médicale, Centre Hospitalier Universitaire and Université de Rouen, 1, rue de Germont, 76031 Rouen, France

^b Laboratoire de Parasitologie-mycologie, EA 3800, Centre Hospitalier Universitaire and Université de Rouen, 1, rue de Germont, 76031 Rouen, France

^c Unité Mixte Internationale 233, TransVIHMI, Laboratoire de Parasitologie-Mycologie médicale; UFR Sciences pharmaceutiques et biologiques, 15, avenue Charles Flahault, B.P. 14491, 34394 Montpellier cedex 5, France

^d L'UNAM Université, Université d'Angers, Groupe d'Etude des Interactions Hôte-Pathogène, EA 3142, Institut de Biologie en Santé-IRIS, Centre Hospitalier Universitaire, 4 rue Larrey, 49933 Angers cedex, France

^e Laboratoire de Parasitologie-Mycologie, Institut de Biologie en Santé-PBH, Centre Hospitalier Universitaire, 4 rue Larrey, 49933 Angers cedex, France

ARTICLE INFO

Article history:

Received 13 June 2012

Received in revised form

23 August 2012

Accepted 28 August 2012

Keywords:

Geosmithia argillacea

Cystic fibrosis

Pulmonary exacerbation

Micafungin

ABSTRACT

Cystic fibrosis (CF) patients are at high risk of colonization of the airways by a number of fungi, including the emerging opportunistic fungus *Geosmithia argillacea*. We report the eradication of respiratory *G. argillacea* associated with clinical resolution of severe symptoms by high-dose and prolonged micafungin therapy in a young CF patient.

© 2012 International Society for Human and Animal Mycology. Published by Elsevier B.V.

Open access under [CC BY-NC-ND license](http://creativecommons.org/licenses/by-nc-nd/4.0/).

1. Introduction

Geosmithia argillacea is presently considered as an emerging opportunistic agent that causes systemic infections in immunocompromised patients with low efficacy of current antifungal therapy despite the use of combinations of 2 to 4 antifungal agents [1–4]. In cystic fibrosis (CF) patients who are at high risk for fungal infections, pathogenic effect of *G. argillacea* can be expected, particularly in case of lung transplantation, since it shares the thermophilic and chronic colonization characteristics of other pathogenic fungi commonly found in the CF context such as *Aspergillus fumigatus* or *Scedosporium apiospermum*, another emerging invasive fungal agent [5–7].

2. Case history

We report the case of a young female patient diagnosed at birth (1996) with F508Del-*CFTR* homozygous CF. She presented

with recurrent severe asthma-like exacerbations not associated with allergy and was chronically colonized by multi-resistant *Staphylococcus aureus* (MRSA) and *Pseudomonas aeruginosa* since 1997 and 2007, respectively. From 2001 to 2006, *A. fumigatus* was recurrently detected in airway secretions, while investigations did not provide evidence for allergic bronchopulmonary aspergillosis or invasive pulmonary aspergillosis. In the context of asthma-like exacerbations, she was alternately treated with oral voriconazole (V-FEND, Pfizer, 200 mg bid.) and itraconazole (Sporanox, Janssen-Cilag, 300 mg per day) from 2004 to 2008, which resulted in *A. fumigatus* eradication in 2006. Nevertheless, due to the detection of other fungi from respiratory specimens, this treatment was continued until 2008. On 2005 and 2006, the presence of *Penicillium* sp. and *Paecilomyces* sp. in sputum specimens was recorded at 3 and 2 occasions, respectively. However these findings were not considered as clinically relevant. On May 23, 2007 (Day 0), *G. argillacea* was recovered for the first time from respiratory secretions, and chronic colonization of the airways by this filamentous fungus was considered as the likely cause of recurrent asthma-like symptoms and of lack of clinical efficacy of antibiotic and antifungal agents (Fig. 1). Morphological identification of *G. argillacea* was confirmed by molecular analysis as described [1]. Briefly, DNA extracted from fungal cultures was amplified by PCR

* Corresponding author. Tel.: +33 232 88 1455; fax: +33 232 88 6875.

E-mail address: loic.favennec@chu-rouen.fr (L. Favennec).

using primers targeting the internal transcribed spacer (ITS-) regions of the rRNA operon. The resulting amplicons were sequenced and the obtained sequences were used in individual BLASTn (Basic Local Alignment Search Tool) searches using NCBI (National Center for Biotechnology Information) BLAST and UNITE databases [8]. In addition, all available *G. argillacea* isolates from this patient were compared by random amplification of polymorphic DNA (RAPD) using the three-primer set M13, NS3 and NS7 which were found the most discriminant among 10 RAPD primers tested with 12 epidemiologically unrelated isolates (Fig. 2). In this patient, chronic colonization with *G. argillacea* lasted 1230 days since day 0. There were 23/28 fungus positive sputum samples, and RAPD analysis of the available isolates revealed that all belonged to the same genotype.

In 2008 (day +533), the patient was treated with posaconazole (Noxafil, Schering-Plough, 400 mg per day) orally, but *G. argillacea* persisted in sputum samples (Fig. 3). In 2009 (from day +882 to

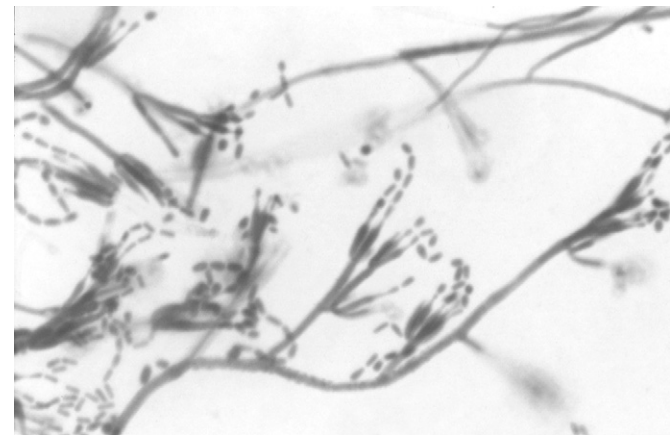


Fig. 1. Microscopic appearance of *Geosmithia argillacea* cultured on Sabouraud dextrose agar medium (magnification $\times 200$). *Geosmithia argillacea* can be recognized by the presence of hyaline, septate and often branched conidiophores bearing biverticillate or terverticillate (occasionally monoverticillate) asymmetrical penicilli, and its smooth-walled, one celled, cylindrical to ellipsoidal conidia produced at the apex of phialides with a cylindrical base tapering more or less abruptly to a narrowed conidium-bearing tube.

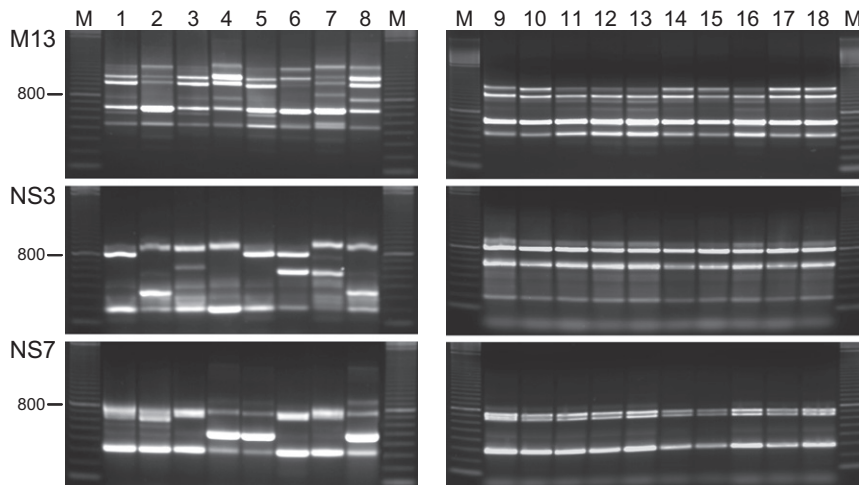


Fig. 2. Electrophoretic patterns of *Geosmithia argillacea* isolates. Electrophoretic patterns of epidemiologically independent isolates recovered from sputum samples collected from March 2009 to February 2011 from distinct patients with CF followed-up in Angers, Giens, Rouen and Paris Necker Hospitals (lanes 1 to 8; #100112439-01, #090654817-01, #110089119-01, #090676598-01, #100421474-01, #090213107-01, #090482165-01 and #100563919-02, respectively). Electrophoretic patterns of patient's isolates (lanes 9 to 18: isolates recovered from sequential sputum samples collected on 2007/04/20, 2007/06/26, 2007/11/12, 2008/10/01, 2008/12/08, 2009/03/16, 2009/06/10, 2010/04/14, 2010/05/17 and 2010/12/13, respectively). Amplicons generated by RAPD using primers M13, NS3 or NS7 were separated on 1.5% agarose gels. Lanes M, DNA size markers (100-bp ladder from GE Healthcare Life Sciences).

day +903), a 3-week caspofungin (Cancidas, MSD) course at a dose of 70 mg per day, later reduced to 50 mg per day due to altered liver enzyme levels, resulted in improved lung function with a FEV1 predicted value increase from 47% to 64% in the absence of *G. argillacea* eradication. In 2010, deterioration in clinical status was observed with frequent severe dyspnoea episodes and a FEV1 predicted value decline to 47% (day +1191). A first 3-week course of micafungin (Mycamine, Astellas Pharma, 75 mg per day, IV) was administered from day +1139 to day +1160 without either clinical improvement or disappearance of *G. argillacea* in sputum. A second course of micafungin started 2 months later (*i.e.* 100 mg bid for 3 weeks and 100 mg per day from day +1219 to day +1261), resulted in clinical and microbiological improvement, with a FEV1 predicted value increase to 68% and *G. argillacea* eradication, mycological cultures from sputum samples remaining sterile for 21 months after initiation of high dose micafungin therapy. No side effect attributable to micafungin therapy was noticed. *In vitro* susceptibility to antifungal drugs was assessed for 6 *G. argillacea* isolates using the microdilution broth reference method (Clinical Laboratory Standards Institute (CLSI) M38-A protocol). The median (range) minimal inhibitory/effective concentrations (MIC/MEC, $\mu\text{g/ml}$) were: 1.0 (0.25–1), 8.0 (2.0–16.0), > 16.0 (> 16.0), 4.0 (2.0–8.0),

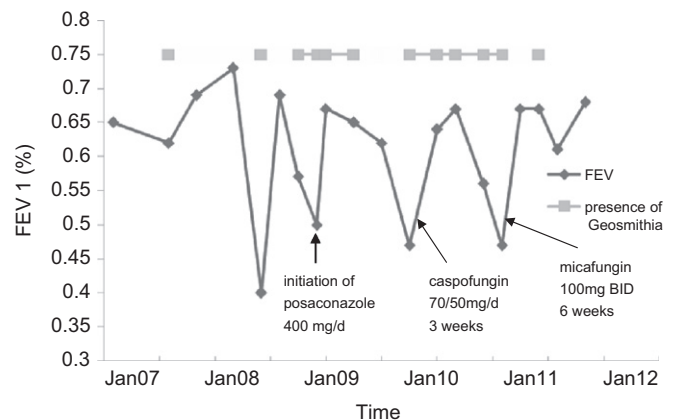


Fig. 3. Evolution of FEV1 predictive values in the course of *Geosmithia argillacea* infection.

0.25 (0.03–0.25) and 0.015 (0.015–0.03) for amphotericin B, itraconazole, voriconazole, posaconazole, caspofungin and micafungin, respectively. From December 2010 (day +1300) until now (day +1846), the patient received posaconazole prophylaxis.

3. Discussion

The pathogenic role of *G. argillacea* in CF is still under discussion. In this patient, *G. argillacea* respiratory colonization was retained as consistent with the deterioration of clinical status and lung function. Each of the three episodes of recovery from the fungus was associated with a dramatic increase in FEV1 predicted values. Moreover, results from RAPD showed that the patient was constantly infected by the same genotype, further supporting chronic colonization of the airways by the fungus. In addition, unchanged bacterial colonization before, during, and after *G. argillacea* colonization, and clinical and functional improvement of the patient after prolonged high dose micafungin-based *G. argillacea* eradication are consistent with a pathogenic role for the fungus. This contrasts with a previous series of 8 CF patients in whom no clinical consequence of *G. argillacea* colonization was reported. However, that only 2/8 patients were persistently colonized and no *G. argillacea* eradication was achieved seems to preclude conclusions [9]. Documented intraspecies sequence divergences in the ITS regions of *G. argillacea* raise also the hypothesis of an heterogeneity of isolates in terms of pathogenicity [10].

In the present patient, the presence of *G. argillacea* in respiratory secretions was ascertained since May 2007, although due to morphological similarities, some 2005 or 2006 isolates may have been misdiagnosed as *Penicillium* and/or *Paecilomyces* species. Respiratory colonization by *G. argillacea* was currently identified in 11/156 CF patients followed-up in Rouen (Normandy, France) University hospital, which questions the role of a mild and wet climate. The origin of the contamination of the patients remains to be defined, and their indoor environment are presently investigated.

As previously reported, isolates from this patient exhibited lower posaconazole MICs than itraconazole MICs, and all were found resistant to voriconazole and to amphotericin B. Nevertheless, they were found less sensitive to itraconazole and posaconazole than those previously studied [2–4]. Differences in sensitivity may be due to prolonged therapy or deficient intestinal azole compound absorption in CF patients. In agreement with other antifungal susceptibility assays, micafungin exhibited lower MEC compared with caspofungin [2]. Until now, all *G. argillacea*-colonized patients treated with antifungal drugs presented with invasive pulmonary infection due to underlying immunodeficiency [2,3]. One patient who received a tritherapy including terbinafine survived. Likewise, another patient survived after receiving a combination of micafungin and posaconazole, while

all other patients who received only one antifungal without lung surgery died [2,3]. In the present case, the first micafungin course given at the commonly recommended dose was inefficient, and *G. argillacea* eradication was achieved only after a prolonged high dose micafungin course.

In summary, the present observation provides first clue for the clinical relevance of *G. argillacea* airway colonization in CF patients. Data prompt further investigation of first intention anti-*G. argillacea* therapy with adapted regimens of micafungin in colonized CF patients.

Conflict of interest

There are none.

Acknowledgments

We thank Dr. Nathalie Donnadieu for her help in providing micafungin.

References

- [1] Giraud S, Pihet M, Razafimandimby B, Carrere J, Degand N, Mely L, et al. *Geosmithia argillacea*: an emerging pathogen in patients with cystic fibrosis. *Journal of Clinical Microbiology* 2010;48:2381–6.
- [2] De Ravin SS, Challipalli M, Anderson V, Shea YR, Marciano B, Hilligoss D, et al. *Geosmithia argillacea*: an emerging cause of invasive mycosis in human chronic granulomatous disease. *Clinical Infectious Diseases* 2011;52:e136–43.
- [3] Machouart M, Garcia-Hermoso D, Rivier A, Hassouni N, Catherinet E, Salmon A, et al. Emergence of disseminated infections due to *Geosmithia argillacea* in patients with chronic granulomatous disease receiving long-term azole antifungal prophylaxis. *Journal of Clinical Microbiology* 2011;49:1681–3.
- [4] Valentin T, Neumeister P, Pichler M, Rohn A, Koidl C, Haas D, et al. Disseminated *Geosmithia argillacea* infection in a patient with gastrointestinal GVHD. *Bone Marrow Transplantation* 2012;47:734–6.
- [5] Symoens F, Knoop C, Schrooyen M, Denis O, Estenne M, Nolard N, et al. Disseminated *Scedosporium apiospermum* infection in a cystic fibrosis patient after double-lung transplantation. *Journal of Heart and Lung Transplantation* 2006;25:603–7.
- [6] Helmi M, Love RB, Welter D, Cornwell RD, Meyer KC. *Aspergillus* infection in lung transplant recipients with cystic fibrosis: risk factors and outcomes comparison to other types of transplant recipients. *Chest* 2003;123:800–8.
- [7] Morio F, Horeau-Langlar D, Gay-Andrieu F, Talarmin JP, Haloun A, Treilhaud M, et al. Disseminated *Scedosporium/Pseudallescheria* infection after double-lung transplantation in patients with cystic fibrosis: case report and review of the literature. *Journal of Clinical Microbiology* 2010;48:1978–82.
- [8] Kõljalg U, Larsson KH, Abarenkov K, Nilsson RH, Alexander IJ, Eberhardt U, et al. UNITE: a database providing web-based methods for the molecular identification of ectomycorrhizal fungi. *New Phytologist* 2005;166:1063–8.
- [9] Barton RC, Borman AM, Johnson EM, Houbraken J, Hobson RP, Danton M, et al. Isolation of the fungus *Geosmithia argillacea* in sputum of people with cystic fibrosis. *Journal of Clinical Microbiology* 2010;48:2615–7.
- [10] Bouchara JP, Hsieh HY, Croquefer S, Barton R, Marchais V, Pihet M, et al. Development of an oligonucleotide array for direct detection of fungi in sputum samples from patients with cystic fibrosis. *Journal of Clinical Microbiology* 2009;47:142–52.